



PRESENTING CLINICAL SIGNS

DATE History: Went into respiratory distress after a dental procedure. Radiographs show an increased bronchial pattern in lower right quadrant consistent with aging. Grade 2/6 murmur. FIV positive.
1/4/22

ECHOCARDIOGRAPHIC FINDINGS

PERFORMED BY:

2D, M-mode, and Doppler study.

Crystal Hill

Left atrial size is normal. The mitral valve is normal. Left ventricular wall thickness is normal. Left ventricular internal dimensions are normal. Left ventricular systolic function is normal. The aorta and aortic valve are normal. Right atrial and right ventricular dimensions are normal. The tricuspid valve appears normal, though very mild tricuspid regurgitation is present. The pulmonary artery and pulmonic valve are normal. No shunting lesions are visualized. No pericardial effusion or cardiac masses are seen.

INTERPRETED BY

Keith Blass, DVM,
MS, DACVIM
(Cardiology)

PATIENT

Doc Burlington
Humane Society

LA/Ao - 1.21
IVSd - 4.6 mm
LVPWd - 4.7 mm
LVIDd - 17.2 mm
LVIDs - 10.2 mm
FS - 40.7%
LVOT - 0.41 m/s
RVOT - 0.60 m/s

SPECIES

ASSESSMENT/RECOMMENDATIONS

Feline

The only abnormality seen in this exam is very mild regurgitation of blood across Doc's tricuspid valve. The hemodynamic effects of the regurgitation are negligible, and Doc's current risk for the development of clinical signs secondary to it is low.

BREED

DSH

No reason for Doc's episode of respiratory distress is seen in this exam.

No therapy is recommended based on this exam.

SEX

A recheck echocardiogram is recommended in 12 months to reevaluate Doc's tricuspid regurgitation.

MN

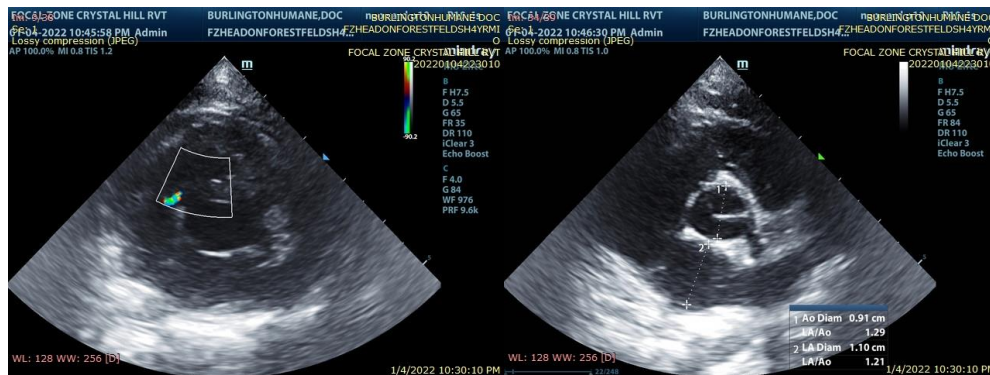
AGE

4 y

WEIGHT

7.16 kg

HOSPITAL NAME



Headon Forest AH

The information and recommendations provided are based on the images presented by the referring veterinarian. No evaluation can be communicated regarding pathology that was not visible in the image/video clips provided.

REFERRING VET

Dr. Hall



Thank you for this referral. If the clinical or image interpretation does not parallel your findings or if I can be of any further assistance please contact me.

DATE

1/4/22

Keith Blass, DVM, MS, DACVIM (Cardiology)
KeithBlass@gmail.com
631-804-5754

PERFORMED BY:

Crystal Hill

INTERPRETED BY

Keith Blass, DVM,
MS, DACVIM
(Cardiology)

PATIENT

Doc Burlington
Humane Society

SPECIES

Feline

BREED

DSH

SEX

MN

AGE

4 y

WEIGHT

7.16 kg

HOSPITAL NAME

Headon Forest AH

REFERRING VET

Dr. Hall